

Case Report

Open Access

Does Long-Term Alendronate Therapy May Lead to Atypical Femoral Fracture near the Hip Prosthesis?

De Li^{1,2}, Hui Wang², Chenglong Wang², Zhuokai Li², Lei Fang², Xiaodong Chen^{2#} and Feng Yin^{1*#}

¹Department of Orthopedic Surgery, East Hospital, Tongji University School of Medicine, China

²Department of Orthopedic Surgery, Xinhua Hospital, Shanghai Jiaotong University School of Medicine, China

#Equal contribution.

Abstract

Osteoporotic fractures are a major public health problem, affecting millions of people worldwide, with oral bisphosphonates favored for their prevention and treatment. Bisphosphonate is a potent inhibitor of osteoclast-mediated bone resorption and is widely used as first-line therapy for the prevention of osteoporotic fractures. It acts by suppressing osteoclastic activity and inducing apoptosis of the osteoclasts. However, there have been increasing reports of atypical femoral fractures which have been identified as a potential complication of long-term alendronate therapy for osteoporosis. So far, there has been few case report in mainland China. Our patient with identified atypical femoral subtrochanteric fracture was reported and similar imaging features of the lateral cortex thickening and beaking could also be seen on the contralateral femoral shaft near the hip prosthesis.

Introduction

In recent years, case reports and a series of cases about atypical femur fractures related to alendronate have been reported one after another [1-3]. Several case series have described cases of atypical subtrochanteric and diaphyseal fractures of the femoral shaft and have suggested that the risk may be increased in long-term users of bisphosphonates [3-6]. So the growing concerns have been raised that the potential malignant effects of alendronate may eventually lead to atypical subtrochanteric and diaphyseal fractures because the subtrochanteric or diaphyseal cortical bone is most susceptible to prolonged bone turnover suppression and accumulated microdamage [7]. Although atypical femoral subtrochanteric fracture in our patient was similar to the series have been previously reported, we found a newly interesting and meaningful imaging performance with the unilateral cortical beaking, and lateral cortical thickening on the contralateral femoral shaft near the distal hip prosthesis.

Case Report

Our patient, a 66-year-old post-menopausal woman has had a medical history of rheumatoid arthritis for 15 years taking a combination of Prednisolone (10 mg

every other day and methotrexate (7.5 mg) weekly for nearly 10 years, suffered an atypical subtrochanteric and diaphyseal femoral fracture in the left hip without any trauma. 2 weeks ago she sometimes had a slight pain and vague discomfort in her left thigh. She had been diagnosed with osteoporosis by bone mineral density scan for 10 years with the administration of alendronate (70 mg) weekly, calcium (1000 mg) daily and calcitriol (0.25 µg) twice a day. The patient has been treated with alendronate therapy for 6 years at the time of her fracture. Owing to rheumatoid arthritis she had a left total knee replacement and a right total hip replacement surgery 7 years ago.

Immediate plain radiographs of her femurs revealed

***Corresponding author:** Feng Yin, Department of Orthopedic Surgery, East Hospital, Tongji University School of Medicine, 150 Jimo Road, Shanghai, 200120, China, Fax: 8602138804518, E-mail: oriental20020123@163.com

Received: March 23, 2017; **Accepted:** June 13, 2017;
Published online: June 16, 2017

Citation: Li D, Wang H, Wang C, et al. (2017) Does Long-Term Alendronate Therapy May Lead to Atypical Femoral Fracture near the Hip Prosthesis?. Adv Tech Musculoskelet Surg 1(1):1-5

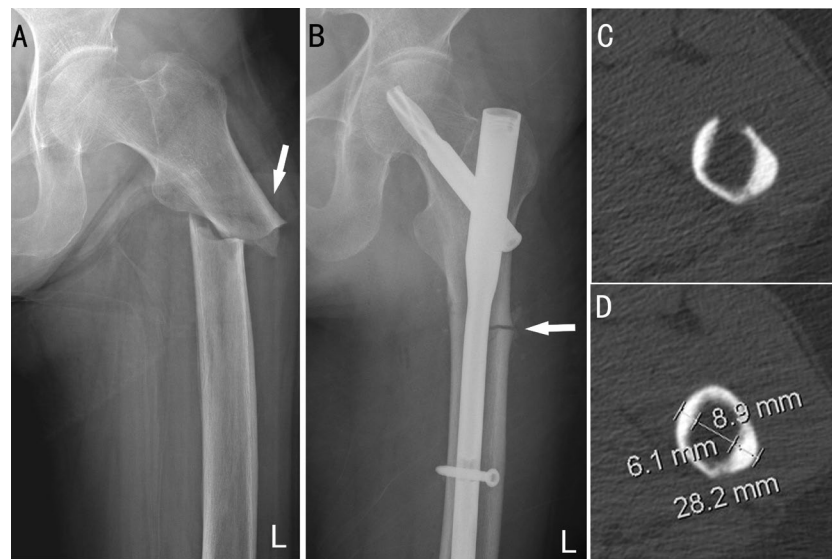


Figure 1: Preoperative radiographs (A) shows a transverse fracture of her left subtrochanteric femoral shaft (arrow); Postoperative radiographs (B) shows diffuse cortical thickening and beaking on the lateral cortex in the subtrochanteric region (arrow); The coronal cuts of CT scans (C,D) reveals that the size of the lateral cortical bone (8.9 mm) is thicker than the medial one (6.1 mm) obviously at the location where the fracture occurred.

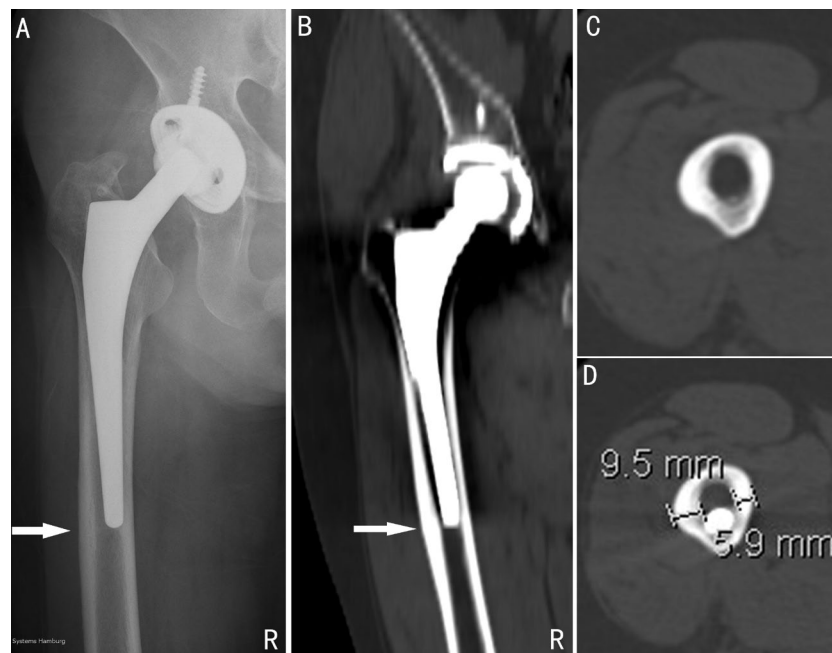


Figure 2: Radiographs (A,B) shows diffuse cortical thickening and beaking on the lateral cortex of the right femoral shaft near the distal hip prosthesis where the stress concentrated (arrow); The coronal cuts of CT scans (C,D) reveals that the size of the lateral cortical bone (9.5 mm) is thicker than the medial one (5.9) obviously at the location where the stress reacts.

a transverse fracture of her left subtrochanteric femoral shaft with the lateral cortex thickening unilaterally. CT imaging showed an 8.9 mm lateral cortical thickening and a 6.1 mm medial one on coronal cuts. A beaking could be seen in the lateral location of the fracture on plain radiographs postoperatively (Figure 1). Similar imaging of stress reaction could also be seen on the contralateral femoral shaft near the hip prosthesis where the stress concentrated. The size of the lateral cortical bone

(9.5 mm), which was located at the distal end of the hip prosthesis, was thicker than the medial one (5.9 mm). Meanwhile, a beaking or spindle could be seen at this area on CT scans or plain radiographs (Figure 2).

When the patient was admitted to our hospital, her general condition was good and no weight loss was observed. The blood pressure stayed at 125/82 mmHg, alkaline phosphatase was 48 units/liter (normal is 35-104), and tumor markers (CEA, carbohydrate antigen 19-9,

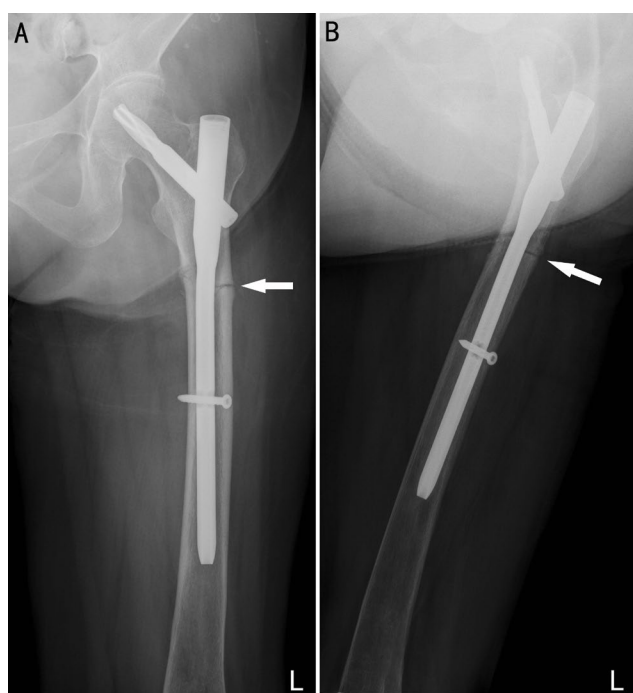


Figure 3: Radiographs (A,B) of left femur at 3-month follow-up showed few callus formation in the region of the subtrochanteric fracture (arrow).

12-5, 15-3 and AFP) were in the normal range. ECG was normal. Chest radiographs showed slight vascular engorgement; no mediastinal mass, calcified or otherwise, was seen. A full blood count, serum kidney and liver functions, as well as an abdominal ultrasound failed to reveal any abnormalities.

In view of the above findings, she was advised to stop alendronate and was taken for Close Reduction Internal Fixation (CRIF) surgery with PFNA- II (proximal femoral nail antirotation- II). Thereafter, she was sent to inpatient rehabilitation and subsequently was discharged home with single-point cane and external fixation brace for the right lower extremity after her stay.

Postoperative 3 months later, plain radiographs failed to reveal obvious callus formation in the areas of the subtrochanteric fracture (Figure 3). Six months after hip surgery, we observed a poor union in the fracture despite discontinuing alendronate therapy. Her fracture had not completely healed after nine months (Figure 4). One year later, the fracture had healed.

Discussion

Alendronate is a specific and potent inhibitor of osteoclast-mediated bone resorption, which has been widely used to treat and prevent osteoporosis and aseptic loosening of prosthesis as well as to treat other bone diseases or tumors [1,2,8]. Facts have proved that it really reduces the overall risk of spine and nonspine fractures among patients with osteoporosis, via decreasing bone

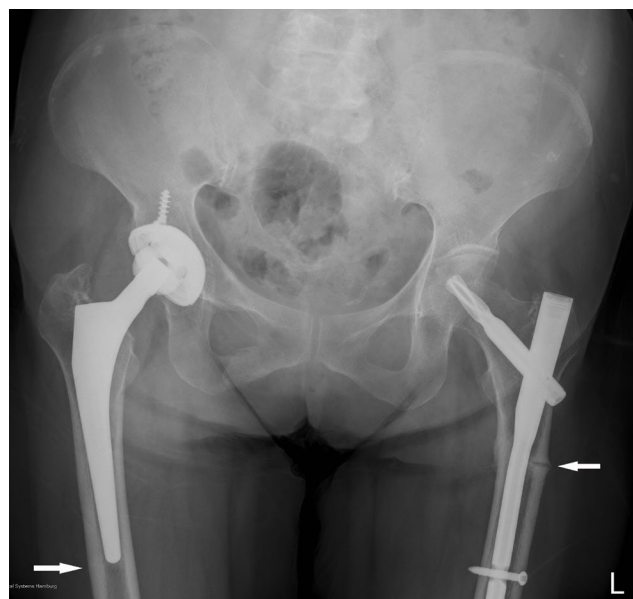


Figure 4: Postoperative 9 months later, radiographs of the left femur showed a poor healing in the fracture despite discontinuing alendronate therapy.

turnover and increasing Bone Mineral Density (BMD), with a long-lasting beneficial effect. Even if the discontinuation of alendronate for up to 5 years, the risk of fractures does not appear to significantly increase [9].

Although alendronate is effective and safe indeed, and well tolerated by most people, its side effects of long-term use are gradually emerged that severe suppression of bone turnover may develop during long-term usage [4,5]. There have been increasing reports of atypical femur fractures associated with alendronate in the literature. Lenart, et al. [3] reported a retrospective case-control study of low-energy femoral fractures with prolonged bisphosphonates use in postmenopausal women osteoporosis. Most patients were found to share a unique radiographic pattern, defined as a simple transverse or short oblique fracture with beaking of the cortex and diffuse cortical thickening of the proximal femoral shaft. Moreover, many of these reported patients had documented prodromal symptoms of thigh pain, vague discomfort, or subjective weakness, for weeks or months before the fracture [10,11]. So these unique clinical and radiographic features surrounding the atypical fractures were found in our patient. The patient had complaints of pre-existing pain in her left hip for two weeks ago prior to the fracture. However, these symptoms were often dismissed or treated as symptoms of spinal stenosis. Therefore, physicians should specifically solicit further information about the thigh and groin pain, and careful scrutiny of the bilateral femur is important. Any patient receiving bisphosphonates who has thigh or groin pain should undergo immediate plain radiographs of the femurs. MRI and bone scanning have greater sensitivity

than radiography for an incipient stress fracture [12]. Pre fracture diagnosis is challenging, but Dual-energy X-ray Absorptiometry (DXA) may be a means of early diagnosis for atypical femoral subtrochanteric and diaphyseal fractures, as it could play a role in early detection of cortical abnormalities [13].

Furthermore, biopsy of bone of the iliac crest after alendronate treatment showed reduced trabecular bone volume and trabecular connectivity, an increased amount of osteoid over the trabecular surface, and increased osteogenesis at the entire interface between osteoid and mineralized bone tested by indirect immunofluorescence [5]. Obviously, it provides further evidence of a potential correlation between prolonged bisphosphonate use and atypical femoral fracture.

Although bisphosphonates may potentially suppress bone turnover, there are other secondary causes and patient-related factors including the use of other antiresorptive or steroid agents, and glucocorticoid, rheumatoid arthritis, hypoparathyroidism, and hypothyroidism [6,14-16]. Moreover, our patient had a similar medical history with rheumatoid arthritis and received glucocorticoid. Glucocorticoid use and rheumatoid arthritis are also associated with an increased risk of atypical femur fractures, with the risk being 5 times as great with glucocorticoid use and 17 times as great with rheumatoid arthritis [14]. However, according to Schilcher, et al. [17], the risk among users of glucocorticoids or proton-pump inhibitors was not higher than nonusers. In any case, the identification of factors that may increase the risk of such complications should help define the proper balance between beneficial effects and potential risks of bisphosphonates in the context of long-term suppression of remodeling [5].

So far, similar cases have not been reported in mainland China. Several factors may have contributed to the development of current situation. Firstly, although, alendronate has been approved by State Food and Drug Administration (SFDA) in China for more than 10 years, a considerable portion of patients could not afford the long-term payment for alendronate, due to high medical costs. In addition, people do not yet pay enough attention to osteoporosis as hypertension and diabetes. Many hospitals also suffer from a shortage of doctors specializing in osteoporosis. Furthermore, both compliance and persistence of patients, in actual practice, is poor and inadequate. To make matters worse, a crisis of confidence emerge between patients and their doctors. It is enough to prove by growing number of medical disputes in recent years in mainland China. On the contrary, there is also evidence to suggest that good compliance and persistence with osteoporosis therapy is helpful to reduce the risk of secondary hip fracture [18,19]. So it is difficult

how to balance alendronate adherence and its impact on the risk of hip-fracture and atypical femur fractures.

Whether bisphosphonate use increases subtrochanteric or diaphyseal femoral fractures is unclear. Based on a national registry, Abrahamsen, et al. [20] reported an increased risk of subtrochanteric fracture with alendronate, but this was attributed to an increased risk of hip fracture, and the risk of diaphyseal fracture was not statistically significant. Black, et al. [21] carried out three large, controlled, blinded, randomized trials to reevaluate of the effect of bisphosphonates on atypical fractures. The result showed that there was no significant increase in risk associated with bisphosphonate use. In addition, the occurrence of fracture of the subtrochanteric or diaphyseal femur was very rare, even among women who had been treated with bisphosphonates for as long as 10 years [17]. A nationwide cohort study described that 59 of all 12,777 women with a fracture of the femur were identified as atypical fractures, and the magnitude of the absolute risk was small and the overall incidence was about 0.25/1000. Although there is an association between atypical subtrochanteric femur fracture and oral bisphosphonate use, clinicians should remember that bisphosphonates significantly reduce the risk of fragility fractures in patients with osteoporosis and that the benefits of fracture prevention with bisphosphonate use will far outweigh their potential risks of atypical femoral fractures [22].

So far, there is no definitive evidence linking over suppression of turnover to atypical fracture. Our data clearly demonstrates that atypical subtrochanteric femoral fracture was identified in the affected thigh and the radiographic features before fracture were found in our patient with beaking of the cortex and diffuse cortical thickening of the contralateral periprosthetic femoral shaft. It is interested for us that there is the similar characteristic of the femoral shaft at the end of hip prosthesis where a stress reaction occurs. Recently, with the rapid development of Chinese economic, alendronate has been widely used to prevent osteoporosis and prosthesis losing after arthroplasty in mainland China. Once the periprosthetic fractures occurred at sites with high tensional stress, it would be very hard to deal with them. We agree that glucocorticoid use and other factors may increase the risk of fractures and that there is need for more research exploring these risk factors alone and their possible interactions with bisphosphonates to increase shaft fracture risk. Our findings suggest that physicians should be cautious not only the hazards of atypical femoral fracture but also the possibility of periprosthetic fractures related to long-term administration of bisphosphonates.

Declarations

Acknowledgments

We acknowledge Mr Hui Wang, Mr Chenglong Wang,

Mr Zhuokai Li and Mr Lei Fang for assistance in data collection Footnotes.

Competing interests

The authors have no conflict of interests.

Ethical approval

Not required.

Funding

None.

Patient consent

Patient/guardian consent was obtained for publication.

References

1. Gunawardena I, Baxter M, Rasekh Y (2011) Bisphosphonate-related subtrochanteric femoral fractures. *Am J Geriatr Pharmacother* 9: 194-198.
2. Rosenberg ZS, La Rocca Vieira R, Chan SS, et al. (2011) Bisphosphonate-related complete atypical subtrochanteric femoral fractures: diagnostic utility of radiography. *AJR Am J Roentgenol* 197: 954-960.
3. Lenart BA, Lorich DG, Lane JM (2008) A typical fractures of the femoral diaphysis in postmenopausal women taking alendronate. *N Engl J Med* 358: 1304-1306.
4. Odvina CV, Zerwekh JE, Rao DS, et al. (2005) Severely suppressed bone turnover: a potential complication of alendronate therapy. *J Clin Endocrinol Metab* 90: 1294-1301.
5. Armamento-Villareal R, Napoli N, Panwar V, et al. (2006) Suppressed bone turnover during alendronate therapy for high-turnover osteoporosis. *N Engl J Med* 355: 2048-2050.
6. Somford MP, Draijer FW, Thomassen BJ, et al. (2009) Bilateral fractures of the femur diaphysis in a patient with rheumatoid arthritis on long-term treatment with alendronate: clues to the mechanism of increased bone fragility. *J Bone Miner Res* 24: 1736-1740.
7. Wasserman N, Yerramshetty J, Akkus O (2005) Microcracks colocalize within highly mineralized regions of cortical bone tissue. *Eur J Morphol* 42: 43-51.
8. Tapaninen TS, Venesmaa PK, Jurvelin JS, et al. (2010) Alendronate reduces periprosthetic bone loss after uncemented primary total hip arthroplasty - a 5-year follow-up of 16 patients. *Scand J Surg* 99: 32-37.
9. Black DM, Schwartz AV, Ensrud KE, et al. (2006) Effects of continuing or stopping alendronate after 5 years of treatment: the Fracture Intervention Trial Long-term Extension (FLEX): a randomized trial. *JAMA* 296: 2927-2938.
10. Kwek EB, Goh SK, Koh JS, et al. (2008) An emerging pattern of subtrochanteric stress fractures: a long-term complication of alendronate therapy? *Injury* 39: 224-231.
11. Bunning RD, Rentfro RJ, Jelinek JS (2010) Low-energy femoral fractures associated with long-term bisphosphonate use in a rehabilitation setting: a case series. *PM R* 2: 76-80.
12. Lenart BA, Lorich DG, Lane JM (2008) More on atypical fractures of the femoral diaphysis. *N Engl J Med* 359: 316-318.
13. Ahlman MA, Rissing MS, Gordon L (2012) Evolution of bisphosphonate-related atypical fracture retrospectively observed with DXA scanning. *J Bone Miner Res* 27: 496-498.
14. Hofbauer LC, Jakob F, Felsenberg D (2010) Bisphosphonates and atypical femoral fractures. *N Engl J Med* 363: 1084.
15. Schneider JP (2006) Should bisphosphonates be continued indefinitely? An unusual fracture in a healthy woman on long-term alendronate. *Geriatrics* 61: 31-33.
16. Demiralp B, Ilgan S, Ozgur Karacalioglu A, et al. (2007) Bilateral femoral insufficiency fractures treated with inflatable intramedullary nails: a case report. *Arch Orthop Trauma Surg* 127: 597-601.
17. Schilcher J, Michaelsson K, Aspenberg P (2011) Bisphosphonate use and atypical fractures of the femoral shaft. *N Engl J Med* 364: 1728-1737.
18. Lin TC, Yang CY, Yang YH, et al. (2011) Alendronate adherence and its impact on hip-fracture risk in patients with established osteoporosis in Taiwan. *Clin Pharmacol Ther* 90: 109-116.
19. Imaz I, Zegarra P, Gonzalez-Enriquez J, et al. (2010) Poor bisphosphonate adherence for treatment of osteoporosis increases fracture risk: systematic review and meta-analysis. *Osteoporos Int* 21: 1943-1951.
20. Abrahamsen B, Eiken P, Eastell R (2009) Subtrochanteric and diaphyseal femur fractures in patients treated with alendronate: a register-based national cohort study. *J Bone Miner Res* 24: 1095-1102.
21. Black DM, Kelly MP, Genant HK, et al. (2010) Bisphosphonates and fractures of the subtrochanteric or diaphyseal femur. *N Engl J Med* 362: 1761-1771.
22. Girgis CM, Sher D, Seibel MJ (2010) Atypical femoral fractures and bisphosphonate use. *N Engl J Med* 362: 1848-1849.